

SONOURETHROGRAPHIC ASSESSMENT OF URETHRAL OBSTRUCTION

Narendra G. Tembhekar¹, Bhawana D. Sonawane², Abhishek Mashirkar³, Prashant U. Titare⁴, Aarti Anand⁵, Pradip B. Rathod⁶

HOW TO CITE THIS ARTICLE:

Narendra G. Tembhekar, Bhawana D. Sonawane, Abhishek Mashirkar, Prashant U. Titare, Aarti Anand, Pradip B. Rathod. "Sonourethrographic assessment of Urethral Obstruction". Journal of Evolution of Medical and Dental Sciences 2014; Vol. 3, Issue 64, November 24; Page: 13971-13978, DOI: 10.14260/jemds/2014/3870

ABSTRACT: BACKGROUND: Previously retrograde urethrography and micturating cystourethrography were used for the evaluation of urethral strictures. Lack of radiation, ability to assess of mucosal and periurethral abnormality and more precise measurement of stricture length makes the sonourethrography an alternative to conventional urethrography. In this article we had reported our experience regarding sonourethrography in cases of anterior urethral strictures. **OBJECTIVES:** Role of sonourethrography in evaluation of anterior urethral abnormalities (especially strictures), Staging and grading of anterior urethral strictures. To compare the utility of sonourethrography as compared to conventional retrograde urography. Role of sonourethrography in diagnosis, management and follow-up of anterior urethral disorders (especially strictures). **MATERIAL AND METHOD:** 70 male patients with obstructive urinary symptoms referred from urology department for retrograde urethrography were selected. Sonourethrographic studies were performed using high frequency probe while injecting saline solution through 12 F Foley's catheter with bulb inflated in the fossa navicularis. Findings were compared with retrograde urethrography and urethroscopy. **RESULT:** Out of total 70 patients who underwent sonourethrogram, 33 patients were diagnosed to have 39 strictures. Out of these 39 strictures, 2 strictures were mild (5.12%), 16 were moderate (41.02%) and 21 were severe (53.84%). 20 strictures were short (focal) while 13 were long (diffuse). One patient had 3 large urethral calculi within the urethral lumen area which were visualised on sonourethrogram. These 39 strictures were also classified under five grade classification proposed by Chiou et al. Of these 39 strictures, 2 classified as GRADE I (5.12%), 6 classified as GRADE II (15.38%), 11 classified as GRADE III (28.20%), 4 classified as GRADE IV (10.25%), 16 came under GRADE V (41.02%). **CONCLUSION:** Sonourethrography can be used as an alternative to retrograde urethrography in the diagnosis of urethral disorder, characterization of urethral strictures and assessing the amount of fibrosis for better management.

KEYWORDS: Sonourethrography, Retrograde Urethrography, Urethral Strictures.

INTRODUCTION: Until recently, diagnostic imaging of the male urethra was dependant on conventional technique with contrast medium to visualize the luminal anatomy. The method of positive pressure urethrography was devised in 1956.¹ Retrograde urethrography as well as micturating cystourethrography are well known techniques for diagnosis of urethral abnormalities. All techniques visualise the anterior and posterior urethra but posterior urethra is better demonstrated on micturating cystourethrography.^{2,3,4}

Retrograde urethrography is the standard imaging study for the diagnosis and management of urethral stricture disease.⁵ Its limitations include poor definition of stricture length & depth of the scar formation. As radiographic urethrography is two-dimensional the appearance of the stricture can vary in accordance with the stretch on the penis and the position of the patient. Variations in patient positioning and penile traction during injection of contrast medium can greatly alter the

ORIGINAL ARTICLE

radiographic appearance of stenotic areas.⁶ Multiple films, including bilateral oblique views are often required. Micturating cystourethrography may provide additional information but may not be effective in the presence of significant strictures. We had used sonourethrography to gain additional information in stricture disease and we found significant improvement over the conventional radiographic examination.

Excellent transrectal visualization of posterior urethra and bladder neck by ultrasound has been reported by sonography. A transeperineal approach with ultrasound to image the posterior urethra has been described in neonates. We present the technique for visualization of anterior urethra using ultrasound. A similar technique had been reported recently.⁷

AIMS & OBJECTIVES:

1. To assess the role of sonourethrography in evaluation of anterior urethral strictures.
2. Staging & grading of anterior urethral strictures
3. To assess the extent of spongiosal and periurethral involvement in cases of urethral strictures.
4. To compare the efficacy of sonourethrography as compared to conventional retrograde urethrography.
5. Role of sonourethrography in the management & follow-up of anterior urethral strictures.

METHODOLOGY: Our hospital based prospective study done in 70 patients of all age group referred from urology department of our hospital with clinical symptoms of urinary obstructions possibly due to urethral strictures with previously done retrograde urethrography were included in our study and evaluated with urethronosography. Patients with symptoms suggestive of acute urethritis, patients with recent instrumentation (procedure postponed for a week) and patients with exclusive posterior urethra involvement were excluded from the study.

Technique of Sonourethrography:

- Patient should lie in a supine frog-leg position to allow easy penile and perineal imaging.
- After sterile preparation of the penis, a small Foley's catheter was introduced about 2 cm deep to urethral meatus then balloon is inflated with 2 to 4 ml of sterile water to occlude the urethral lumen so that the catheter secure in position.
- Manually inject the saline through the Foley's catheter to distend the urethral lumen for the examination. With variable irrigation pressures, the caliber and distensibility of the urethra was assessed.
- Transducer was placed on the ventral surface of the penis overlying the urethra to image the penile and the distal portion of the bulbous urethra. Transducer was placed perineally to image the proximal bulbous urethra. Color doppler imaging was helpful to assess the location of urethral arteries and the bulbar spongiosal blood flow.

Urethral stricture was assessed for length, spongiosal tissue involvement and degree of occlusion.

RESULTS: Among the total 70 cases, age distribution was done in the following groups: 11 to 20 year - 6 patients (8.57%), 21 to 30 years - 8(11.42%), 31 to 40 year-13(18.57%), 41 to 50 year -14 (20.00%), 51 to 60 year -15 (21.42%), 61 to 70 year-7 (10.00%), 71 to 80 year- 4 (5.71%) (Chart 1).

ORIGINAL ARTICLE

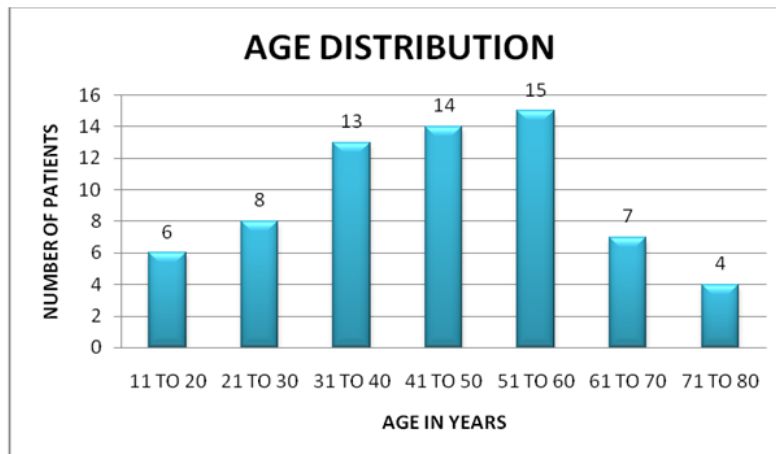


Chart 1: Chart showing age distribution in our patients

Symptom evaluation had revealed retention of urine in 47 patients (67.14%), dysuria in 5 cases (7.14%), Thin stream in 37 cases (37%), burning micturition in 35 cases (50%), abdominal pain in 8 cases (11.42%), increased urine frequency in 22 cases (31.42%), hematuria in 10 cases (14.28%), pyuria in 10 cases (14.28%), dribbling in 30 cases (42.85%), scrotal swelling in 1 case (1.42%), prostatomegally in 23 cases (32.85%), significant post void residual urine in 28 cases (40%), incontinence in 6 cases (8.57%), enuresis in 9 cases (12.85%), chyluria in 1 cases (1.42%), congenital defect in 1 case (1.42%), anorexia in 2 cases (2.85%), nausea in 2 cases (2.85%), constipation in 1 case (1.42%), colitis in 1 case (1.42%), piles in 1 case (1.42%), suprapubic catheterisation in 8 cases (11.42%).

Out of the 70 patients who underwent sonourethrogram 33 patients had 39 strictures out of which, 2 strictures were mild (5.12%), 16 were moderate (41.02%) and 21 were severe (53.84%) (Chart 2, Figure 1). Twenty strictures were short (focal) while 13 were long (diffuse). Three patients had posterior urethral stricture out of these only one can be visualised on sonourethrogram.

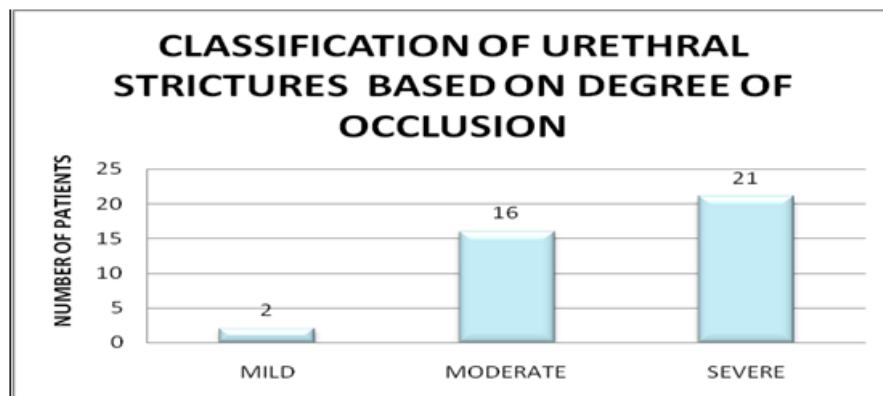


Chart 2: Chart showing staging of urethral strictures

ORIGINAL ARTICLE

Figure 1: Retrograde urethrographic (peripheral) images and corresponding sonourethrographic (central) images showing staging of urethral strictures.

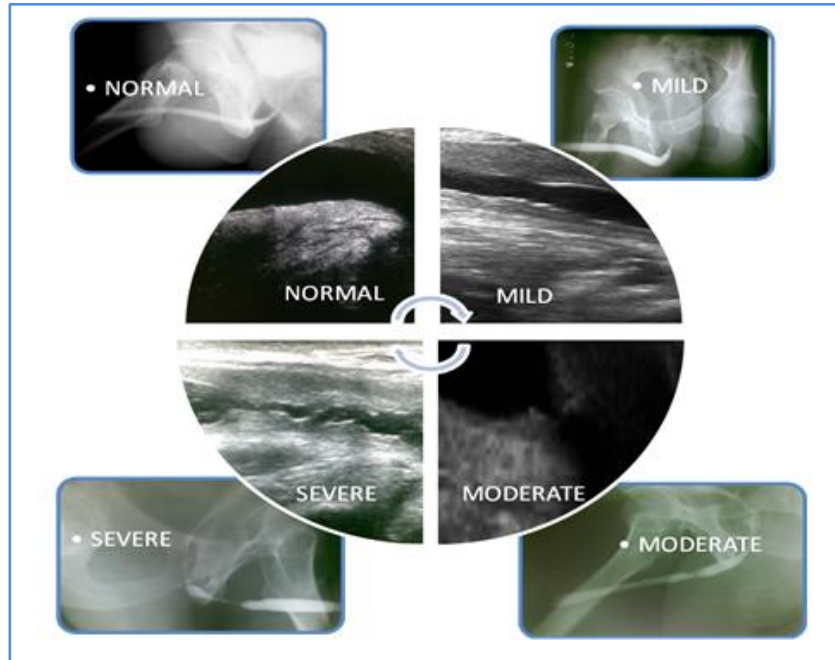


Figure 1

These 39 strictures classified under five grade classification proposed by Chiou et al. Of these 39 strictures, 2 were classified as GRADE I (5.12%), 6 classified as GRADE II (15.38%), 11 classified as GRADE III (28.20%), 4 classified as GRADE IV (10.25%), 16 came under GRADE V (41.02%) (Chart 3, Figure 2).

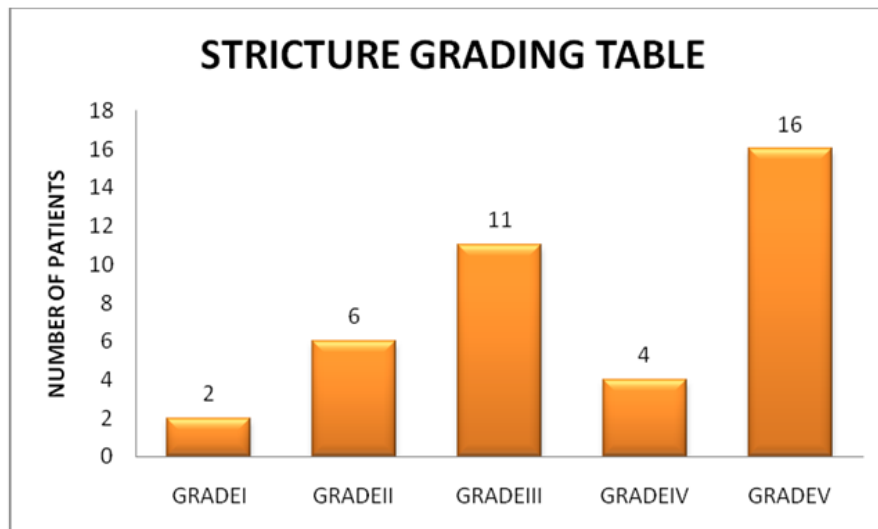


Chart 3: Chart showing grading of urethral strictures

ORIGINAL ARTICLE

Figure 2: Sonourethrographic images showing grading of urethral strictures.

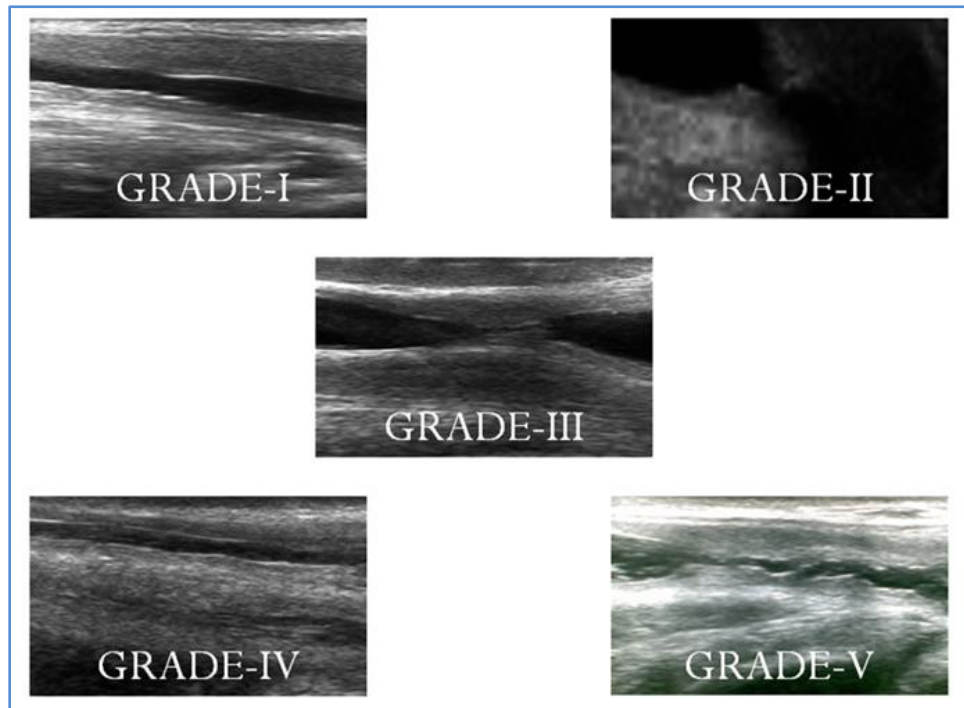


Figure 2

In our study we found three patients with posterior urethral strictures out of these only one was visualised on sonourethrogram and one patient had three large urethral calculi within the urethral lumen area which were visualised on sonourethrogram but not on the retrograde urethrogram. Sonourethrogram found superior in evaluating, periurethral fibrosis (three cases), urethral calculi (three in number), mucosal thickening (two cases), mucosal flap (two cases), urethritis (eleven patients)

DISCUSSION: In our study maximum patients were of age group 50-60 year and most common symptom was retention of urine. The staging of urethral strictures done according to the degree of luminal occlusion (Table 1).⁸ Our maximum patients were in the severe stage.

S. N.	Urethral stricture staging	Sonographic findings
1	Mild	< one third lumen occluded.
2	Moderate	One third to half of the lumen occluded.
3	Severe	Greater than half of the lumen occluded.

Table 1: Table showing stages of urethral strictures

Chiou et al had proposed the grading of urethral stricture depending on the number and length of stricture, amount of spongiosal tissue involvement (Table 2).⁹ Our maximum cases were had grade V stricture.

ORIGINAL ARTICLE

S. N.	Stricture grading	Sonographic findings
1	I	Short stricture with minimal spongiosal tissue involvement
2	II	Short stricture with moderate spongiosal tissue involvement
3	III	Short stricture with extensive spongiosal tissue involvement
4	IV	Long or multiple strictures with moderate spongiosal tissue
5	V	Long or multiple strictures with extensive spongiosal tissue

Table 2: Table showing grades of urethral strictures

In 1994 S Gupta et al studied 30 patients in which stricture grading was as follows (Table 3).¹⁰

	Total patients	Total Graded strictures	Mild Grade	Moderate Grade	Severe Grade
Gupta et al (1994)	30	16	5	2	9
Present study	70	39	2	16	21

Table 3: Table showing grades of urethral strictures in the study done by Gupta et al and our study

In 1988 Mcaninch et al studied a total of 17 patients with suspected stricture disease and found that sonourethrography was more accurate than RGU.⁷

In 2004 S Choudhary et al had studied a comparison of sonourethrography and retrograde urethrography in evaluation of anterior urethral strictures and concluded that retrograde urethrogram and sonourethrography are equally efficacious in detection of anterior urethral strictures. Further characterization of strictures in terms of length, diameter and periurethral pathologies, like spongiofibrosis and false tracts, is done with greater sensitivity using sonourethrography as compared with retrograde urethrogram, with the added benefit of lower incidence of complications.¹¹

In our study all patients with anterior urethral strictures were diagnosed by sonographic urethrogram and by retrograde urethrogram. Retrograde urethrogram and sonourethrography were equally efficacious in detection of anterior urethral strictures. Further strictures characterization and periurethral pathologies like spongiofibrosis were better shown on sonourethrography as compared with retrograde urethrogram with less complication. The echogenic appearance of collagen tissue within the stricture did not allow ultrasound per se to distinguish between normal and involved spongiosum. However when the urethra was distended with saline as done in sonourethrography, differentiation becomes easy. Sufficient information thereby was provided to measure length and diameter of the stricture tissues and to estimate the degree of spongiofibrosis.

Among three posterior urethral strictures on retrograde urethrogram only one was demonstrated on sonourethrogram suggestive of limitations of sonourethrogram in determining posterior urethral stricture. Sonographic evaluation of the posterior urethra was technically limited despite of transscrotal approach owing to inability to scan the urethra in a perpendicular fashion.

ORIGINAL ARTICLE

In contrast all the anterior urethral strictures can be demonstrated and staging could be possible on sonourethrograph more accurately and precisely. The sonographic urethrograph in two patients with a history of urethritis showed evidence of mucosal septation/filling defect, in which its dimensions can be taken effectively on sonourethrograph.

The contrast used in retrograde urethrograph is costly and can cause allergic reactions while the contrast used in sonourethrograph (normal saline) is comparatively cheaper and non-reactive. Multiple views were required to study strictures. Such multiple views increase the cost of the procedure in retrograde urethrography but not on sonourethrograph. Thus the sonourethrograph is cost effective procedure.

Out of the 70 patients 61 preferred the sonographic urethrograph over the roentgenographic procedure. Neither patient had bleeding nor did they complain of discomfort during the sonourethrography which were reported in some cases in retrograde urethrography.

As it provides reproducible quantitative information, sonourethrography is influential in planning surgical interventions. For short bulbar strictures ultrasound measures stricture length more accurately than conventional radiographic retrograde urethrography and therefore it helps in determining whether to excise or graft. The simplicity, precision and availability of sonography, with the absence of radiation exposure, make sonourethrography a valuable staging tool for the urologist.

Sonourethrography has a major influence on selection of therapy in patients with bulbar strictures of intermediate length. By prospectively identifying strictures too long for resection and end-to-end anastomosis, sonourethrography enables quantitative criteria for selection of patients who may be more appropriately treated by flap or graft procedures.

Thus we recommend the use of sonourethrography as a best alternative to conventional retrograde urethrography for the evaluation of anterior urethral strictures.

CONCLUSION: Sonourethrography in experienced hand proved to be beneficial alternative to retrograde urethrography for the diagnosis and characterization of anterior urethral strictures and assessing the amount of fibrosis making it a cheap, cost effective, nonradiative valuable imaging tool in surgical management. Thus hereby we are recommending the use of sonourethrography as an alternative to retrograde urethrography.

REFERENCES:

1. Davis HJ, Cian LG. Positive Pressure Urethrography: A New Diagnostic Method. *J Urol.* 1956; 75 (4): 753-7.
2. Kratochwil A, Wiltschke H, Schon R, Weissenbacher G. Zur Diagnose der hinteren Harnrohrenklappe. *Urologe* 1972; 11: 263.
3. Chambers RM, Baitera B. The Anatomy of the Urethral Stricture. *Br J Urol.* 1977 Nov; 49 (6): 545-51.
4. McCallum RW. The Adult Male Urethra: Normal Anatomy, Pathology, And Method Of Urography. *Radiol Clin North Am.* 1979; 17: 227-44.
5. Devine CJ. Surgery of the urethra. *Campbells urology*, Fifth ed. Edited by P.C.walsh, R.F.Gitteset al, Vol -3, Section XV, Chapt. 80, 2853-2887, 1986.
6. Rosen MA, McAninch JW. Preoperative staging of anterior urethral stricture. *Traumatic and reconstructive urology.* Edited by J.W. Mc Aninch Philadelphia: W. Saunders, Chapt. 46, 551-564, 1996.

ORIGINAL ARTICLE

7. Jack W. Mcaninch et al. Sonourethrography in The Evaluation Of Urethral Strictures: A Preliminary Report. J. Urology 1988; 139: 294-7.
8. Debus-Thiede et al: First experiances with transvaginal sonography of the urethra and urinary bladder as part of incontinance diagnosis. Geburtshilfe frauenheilk, 45: 891, 1985.
9. Chiou RK, Anderson JC, Tran T, Ptterson RH, Wobig R, And Taylor RJ. Evaluation Of Urethral Strictures And Associated Abnormalities Using High-Resolution And Color Doppler Ultrasound. Urology. 1996; 47: 102-7.
10. S Gupta, B Majumdar, A Tiwari, R K Gupta, A Kumar, and R B Gujral. Sonourethrography in the Evaluation of Anterior Urethral Strictures: Correlation with Radiographic Urethrography. Arch Ital Urol Androl. 1994; 66 (4): 113-7.
11. Choudhary S, Singh P, Sundar E, Kumar S, Sahai A. A Comparison of Sonourethrography and Retrograde Urethrography in Evaluation of Anterior Urethral Strictures. Clin Radiol. 2004; 59 (8): 736-42.

AUTHORS:

1. Narendra G. Tembhekar
2. Bhawana D. Sonawane
3. Abhishek Mashirkar
4. Prashant U. Titare
5. Aarti Anand
6. Pradip B. Rathod

PARTICULARS OF CONTRIBUTORS:

1. Associate Professor, Department of Radiology, Government Medical College and Super Speciality Hospital, Nagpur, Maharashtra, India.
2. Professor, Department of Radiology, Government Medical College and Super Speciality Hospital, Nagpur, Maharashtra, India.
3. Junior Resident, Department of Radiology, Government Medical College and Super Speciality Hospital, Nagpur, Maharashtra, India.
4. Assistant Professor, Department of Radiology, Government Medical College and Super Speciality Hospital, Nagpur, Maharashtra, India.

5. Associate Professor, Department of Radiology, Government Medical College and Super Speciality Hospital, Nagpur, Maharashtra, India.
6. Assistant Professor, Department of Radiology, Government Medical College and Super Speciality Hospital, Nagpur, Maharashtra, India.

NAME ADDRESS EMAIL ID OF THE CORRESPONDING AUTHOR:

Dr. Narendra G. Tembhekar,
Abhiyanta Colony,
Ganeshpur, Bhandara (M. S.),
Maharashtra, India.
Email: shalinitembhekar@gmail.com

Date of Submission: 14/11/2014.
Date of Peer Review: 15/11/2014.
Date of Acceptance: 19/11/2014.
Date of Publishing: 21/11/2014.